

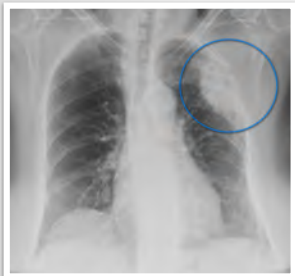

Localization of disease in the thorax

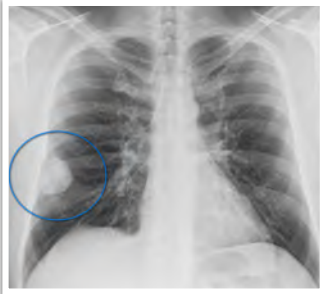Characterization method

What will I gain from this video?

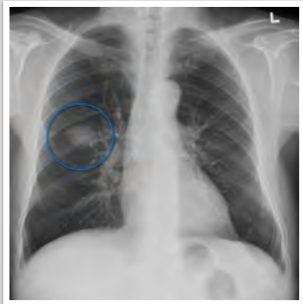
After watching this video, you will be able to use the characterization method to narrow down potential localization of disease within the thorax.



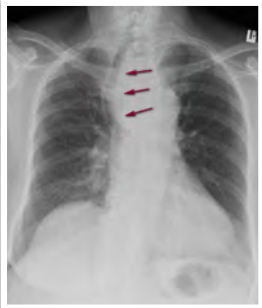
Rib destruction



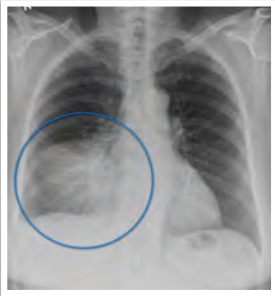Lack of a border



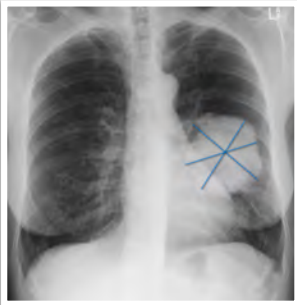
Clear borders



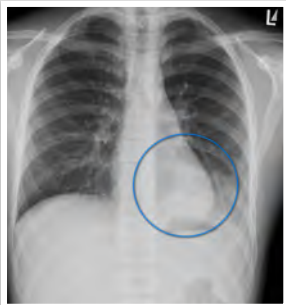
Mass effect



Silhouette sign



Epicenter



Air bronchogram

Central mass and tracheal shift—think mediastinum

Air bronchograms—think lungs

Rib destruction—think chest wall

Silhouette sign—think lungs
